

Outcome Analysis in Cases of Spinal Conus Cauda Ependymoma

SRIKANT BALASUBRAMANIAM¹, DEVENDRA K TYAGI², KETAN I DESAI³, MOHNISH P DIGHE⁴

ABSTRACT

Introduction: One half of all central nervous system ependymomas, arise within the spinal canal and about 40% of these arise from filum terminale. The myxopapillary variant of spinal ependymoma almost exclusively occurs in the lumbosacral region and they are histologically designated as Grade I. Long term control is best achieved by gross total removal at the initial operation. There is as yet no consensus on the management of incompletely excised tumour. Opinions regarding radiotherapy are controversial and the indications are empirical.

Aim In the present study, we investigated the clinical characteristics and long-term outcomes in patients with conus cauda ependymoma that were managed at our center with baseline comparison of our findings with those reported in literature.

Materials and Methods: A retrospective analysis of 44 cases of conus cauda ependymoma tumours treated at the Department of Neurosurgery at a tertiary care centre from January 2001 to December 2015 was done. Detailed scrutiny and analysis of the patient's data with respect to the demographic features, clinical findings, investigative procedures, extent of surgical resection, intra and postoperative complications, efficacy of adjuvant

therapy, postoperative results and long term follow-up were done.

Results: The analysis was done in 44 patients with conus cauda ependymoma over a period of 15 years. The mean age of presentation was 31 years. Incidence of male predominance was noted. Average duration of presenting features was 10 months. Back pain and motor weakness in the lower limbs were the commonest clinical findings. Total excision of the tumour was possible in 89% cases. Myxopapillary ependymoma was the commonest variant. Radiotherapy was only given in patients with near total to subtotal excision of tumour. Back pain and motor weakness improved in majority of patients after surgery. There is limited role of radiotherapy in cases with total tumour excision.

Conclusion: Conus cauda ependymomas are relatively benign tumours. The long term prognosis is excellent with respect to recurrence and functional outcome in cases with complete tumour excision. Early diagnosis and surgery will prevent occurrence of permanent neurological deficits. Radiotherapy can be given in cases of subtotal excision but there is limited role of radiotherapy in cases with total tumour excision.

Keywords: Cauda equina tumours, Conus medullaris tumours, Lumbosacral ependymoma, Myxopapillary ependymoma

INTRODUCTION

One half of all central nervous system ependymomas arise within the spinal canal [1,2]. Spinal ependymomas are common in adults, unlike the paediatric age group where ependymomas arise more often intracranially [3]. Most of the spinal ependymomas are intramedullary, of which 40% arise from the filum terminale [4].

Our understanding of these tumours has been on the basis of pioneering work of Cushing, Bailey and Kernohan [5-7].

The myxopapillary variant of spinal ependymoma almost exclusively occurs in the lumbosacral region [8]. Papillary or myxopapillary ependymomas of the lumbosacral region are generally regarded as relatively benign slow growing tumours. In the International histological classification of tumours published by the World Health Organization this tumour variant is histologically designated as Grade I. These tumours have been diagnosed and surgically addressed for more than a hundred years.

Even though there are subtle differentiating points between spinal tumours in the conus medullaris and cauda equina regions, they usually present with a combination of symptoms [9]. The recent improvement in neuro-imaging techniques has allowed these lesions to be diagnosed early and accurately [10]. Direct surgical removal of these tumours is perhaps the most straight forward and logical approach to the problem [11]. With the advent of operating microscope, development of microsurgical techniques, imaging

technologies and intraoperative neurophysiology the strategy for these neoplasms is further evolving. In the group of intramedullary tumours, spinal ependymomas are amongst those for which total surgical removal has given satisfying clinical results [4,12]. Long term control is best achieved by gross total removal at the initial operation [12].

Although it is widely believed that the desirable treatment is total excision, there is as yet no consensus on the management of incompletely excised tumour. Opinions regarding radiotherapy are controversial and the indications are empirical [13,14]. Despite the risk of local recurrence and CSF dissemination, the overall prognosis for lumbosacral intradural ependymomas appears to be very good with survival rates in the range of 95% over 10 years [15]. In the present study, we investigate the clinical characteristics and long-term outcomes in patients with conus cauda ependymoma that were managed at our center with baseline comparison of our findings with those reported in literature.

MATERIALS AND METHODS

Study design and cohort: A retrospective, single-institutional study conducted at BYL Nair Hospital, Mumbai involving 44 patients undergoing surgical excision for conus cauda ependymoma between January 2001 and December 2015 was performed. Ethical approval was obtained from the institutional ethical board committee prior to initiation of the study. All consecutive cases

of histologically confirmed ependymoma cases in the conus medullaris and cauda equina region were included in our study.

Data-extraction: This included review of patient medical records for eligible patients. Detailed scrutiny and analysis of the patient's data with respect to the demographic features, clinical findings, and investigative procedures, extent of surgical resection, intra and postoperative complications, efficacy of adjuvant therapy, postoperative results and long term follow-up were done [Table/Fig-1].

Study Protocol: In all patients who underwent surgery, routine hematological workup and Magnetic Resonance Imaging (MRI) scan of the lumbosacral spine was performed. Laminectomies with respect to the extent of tumour were done in all patients in our series. After opening the dura in midline, the edges were reflected away and held with stay sutures. The excision of tumour was done in a piecemeal fashion, preserving the nerve rootlets. Based on the involvement/ infiltration of nerve rootlets and conus by the tumour, the extent of excision was subtotal to total. Once the excision was complete, the dura was closed in a water tight manner with absorbable vicryl sutures. Postoperative neurological status and complications were studied. In our series MRI scan was done in all 44 patients during their follow up visits. Preoperative and postoperative neurological and functional outcome were studied and compared.

Follow-up was obtained either by clinical records or by personal communication through letters. Patients with subtotal tumour excision were subjected to adjuvant radiotherapy. Radiotherapy was deferred in those patients where complete tumour excision was performed and these patients were closely observed. All such patients were monitored with serial MRI scans to detect any recurrence during subsequent follow-up visits. In our series four patients had no follow-up after surgery and were hence excluded from our study.

STATISTICAL ANALYSIS

Descriptive statistics were employed for projection of results in the form of frequencies and proportions of categorical variables and mean± SD (range) for quantitative variables.

RESULTS

Back pain and lower limb weakness were the predominant presenting symptoms. Sphincter disturbances in the form of incontinence/retention of urine, enuresis and constipation were present in 15 (34%) patients. Sexual dysfunction in the form of impotency and premature ejaculation was noted in 6 patients. In 2 patients, there was kyphotic deformity of the lumbar spine and 1 patient had valgus deformity of the foot at the time of presentation to us [Table/Fig-1].

In 39 patients, the excision of tumour was complete (total). In 1 patient subtotal excision was performed as the tumour was infiltrating the rootlets and conus medullaris. In 4 patients, the excision was near total and a small portion of the tumour was left behind, that was densely adherent to the rootlets [Table/Fig-1,2].

In majority of patients at follow-up, back pain and motor weakness improved, when compared with their preoperative status. However, the sphincter problem improved in only 25% patients after the surgery [Table/Fig-3].

During follow-up visits in 39 (89%) patients there was no evidence of residual or recurrent tumour on MRI scans. In these patients, total excision of the tumour was done. These patients were clinically asymptomatic. In 5 (11%) patients there was residual tumour on follow-up MRI scans. The extent of excision in these patients was near total to subtotal. Clinically they were pain free, but the motor weakness in lower limbs and sphincter disturbances persisted. These patients were subjected to Radiotherapy (RT).

Sr. No.	Characteristic	Value
1.	Age, in years Mean ± SD Range	30.95 ± 12.78 Max 63, Min 3
2.	Gender, n(%) Male Female	35 (80%) 9 (20%)
3.	Symptom duration, in months Mean ± SD Range	9.52± 9.27 Max 36, Min 1
4.	Presenting Symptoms, n(%) Back pain Lower limb weakness Difficulty in walking Sensory symptoms Bowel/bladder complaints Sexual dysfunction Deformity	40 (91%) 37 (84%) 36 (82%) 19 (43%) 15 (34%) 6 (14%) 3 (7%)
5.	Presenting Signs, n(%) Motor weakness in lower limbs Altered tone Hypotonia Hypertonia Deranged Reflexes Absent Brisk Lower limb hypoesthesia	37 (84%) 24(55%) 4(9%) 27(61%) 3(7%) 24(55%)
6.	Surgical Resection, n (%) Total Near Total Subtotal	39 (88.6%) 04 (9.1%) 01 (2.3%)
7.	Length of stay, days Mean ± SD Range	12.07± 14.01 Max 85, Min 3
8.	Postoperative complications, n(%) Wound infection Urinary retention Motor weakness Dysesthesia	2 (4.5%) 3 (7%) 2 (4.5%) 1 (2.3%)
9.	Histopathology, n(%) Myxopapillary Ependymoma Cellular Ependymoma Clear Cell Ependymoma Anaplastic Ependymoma	24 (55%) 17 (39%) 1 (2.3%) 2 (4.5%)
10.	Follow up, in months Mean± SD Range	22.23± 11.32 Max 48 Min 6
11.	Recurrence Rate, n(%)	2 (4.5%)
12.	Long term functional outcome, n(%) Good Fair Poor	28(63.6%) 9(20%) 7(15%)

[Table/Fig-1]: Patient characteristics of 44 patients with conus cauda ependymoma seen at our institute between 2001- 2015.

In 2 patients, recurrence was noted at 1 year follow-up. Both these patients were histologically of anaplastic variant. They were symptomatic and motor weakness in lower limbs had deteriorated. One patient of which was re-operated and near total excision of the tumour was performed. MRI scan of second patient revealed a large recurrence of tumour and was advised surgery. He however failed to follow-up with us.

In assessing long-term results the Beniamino Classification was used [16].

Good- (70-90% of normal): Minimal neurological abnormality such as weakness of limbs, sensory abnormality, mild sphincter trouble, walks unaided with support and is independent.

Fair- (50-70% of normal): Moderate neurological deficit walks with stick or crutches, reasonably independent.

Poor- (30-50% of normal): Gross neurological deficits, walks with support, has gross sphincter and motor disturbances, totally dependent on others for life.

Most of the patients who had poor functional outcome were having severe neurological deficits at the time of presentation [Table/Fig-1].

Sr. No.	Age (Years)	Sex (M/F)	Operative Procedure			Histopathology Report
			Procedure	Findings	Type of Resection	
1	25	M	D12-L3 laminectomy	Soft, Fleшы, vascular tumour	Total	Myxopapillary ependy
2	45	M	D12-L1 laminectomy	Soft, Fleшы, vascular tumour	Total	Cellular ependymoma
3	40	F	L4-S1 laminectomy	Firm and mildly vascular	Total	Myxopapillary ependy
4	38	M	D12-L3 laminectomy	Soft, Fleшы, vascular tumour	Near total	Cellular ependymoma
5	30	M	D12-L2 laminectomy	Soft, Fleшы, vascular tumour	Near total	Myxopapillary ependy
6	29	M	L3-S3 laminectomy	Soft, Fleшы, vascular tumour	Total	Myxopapillary ependy
7	38	M	D12-L3 laminectomy	Firm, Fleшы, vascular tumour	Total	Myxopapillary ependy
8	40	F	L1-L2 laminectomy	Soft, Fleшы, vascular tumour	Total	Cellular ependymoma
9	32	M	L1-L2 laminectomy	Soft, Fleшы, vascular tumour	Total	Myxopapillary ependy
10	50	M	L3-S1 laminectomy	Soft, Fleшы, vascular tumour	Total	Myxopapillary ependy
11	40	M	L3-S1 laminectomy	Partly solid and partly cystic	Near total	Anaplastic ependymoma
12	15	M	L1-S2 laminectomy	Firm and mildly vascular	Total	Myxopapillary ependy
13	51	M	L1-L3 laminectomy	Firm and mildly vascular	Total	Myxopapillary ependy
14	27	F	D12-L5 laminectomy	Soft, Fleшы, vascular tumour	Total	Myxopapillary ependy
15	3	M	L1-L5 laminectomy	Firm and mildly vascular	Subtotal	Anaplastic ependymoma
16	63	M	L3-S1 laminectomy	Soft, Fleшы, vascular tumour	Total	Cellular ependymoma
17	35	M	L2-L4 laminectomy	Soft, Fleшы, vascular tumour	Total	Myxopapillary ependy
18	35	M	L1-L4 laminectomy	Soft, Fleшы, vascular tumour	Total	Cellular ependymoma
19	20	M	D12- L3 laminectomy	Soft, Fleшы, vascular tumour	Total	Myxopapillary ependy
20	36	M	L2-L5 laminectomy	Soft, Fleшы, vascular tumour	Total	Myxopapillary ependy
21	14	M	L1-L3 laminectomy	Soft, Fleшы, vascular tumour	Total	Myxopapillary ependy
22	22	M	L1-L4 laminectomy	Soft, Fleшы, vascular tumour	Total	Cellular ependymoma
23	26	M	L1-L3 laminectomy	Soft, Fleшы, vascular tumour	Total	Myxopapillary ependy
24	41	M	L1-L2 laminectomy	Soft, Fleшы, vascular tumour	Total	Cellular ependymoma
25	12	M	L1-S3 laminectomy	Soft, Fleшы, vascular tumour	Total	Myxopapillary ependy
26	27	M	D12-L1 laminectomy	Soft, Fleшы, vascular tumour	Total	Myxopapillary ependy
27	15	M	L1-L4 laminectomy	Soft, Fleшы, vascular tumour	Total	Myxopapillary ependy
28	50	F	D12-L2 laminectomy	Soft, Fleшы, vascular tumour	Total	Cellular ependymoma
29	45	M	L1-L3 laminectomy	Soft, Fleшы, vascular tumour	Total	Cellular ependymoma
30	28	M	L1-L3 laminectomy	Soft, Fleшы, vascular tumour	Total	Cellular ependymoma
31	35	F	L1-L3 laminectomy	Soft, Fleшы, vascular tumour	Total	Cellular ependymoma
32	45	M	D12-L2 laminectomy	Soft, Fleшы, vascular tumour	Total	Myxopapillary ependy
33	17	M	L1-L3 laminectomy	Soft, Fleшы, vascular tumour	Total	Cellular ependymoma
34	34	M	D12-L2 laminectomy	Firm, Fleшы, vascular tumour	Near total	Myxopapillary ependy
35	25	F	D12-L2 laminectomy	Firm, Fleшы, vascular tumour	Total	Cellular ependymoma
36	50	F	L1-L2 laminectomy	Firm, Fleшы, vascular tumour	Total	Cellular ependymoma
37	27	M	D12-L2 laminectomy	Firm, Fleшы, vascular tumour	Total	Cellular ependymoma
38	34	M	D12-L2 laminectomy	Firm, Fleшы, vascular tumour	Total	Myxopapillary ependy
39	24	M	L1-L2 laminectomy	Firm, Fleшы, vascular tumour	Total	Cellular ependymoma
40	19	M	L4-S1 laminectomy	Firm, Fleшы, vascular tumour	Total	Myxopapillary ependy
41	22	M	D12-S1 laminectomy	Firm, Fleшы, vascular tumour	Total	Myxopapillary ependy
42	31	F	L1-L5 laminectomy	Firm, Fleшы, vascular tumour	Total	Clear cell ependymoma
43	13	F	D12-L5 laminectomy	Firm, Fleшы, vascular tumour	Total	Cellular ependymoma
44	14	M	D12-L2 laminectomy	Firm, Fleшы, vascular tumour	Total	Myxopapillary ependy

[Table/Fig-2]: Intraoperative finding in our series.

Symptom	Improvement	No improvement	Worsening
Pain (N= 40)	36 (90%)	4 (10%)	0
Motor weakness (N= 37)	26 (70%)	7 (19%)	4 (11%)
Sensory disturbances (N= 19)	10 (53%)	8 (42%)	1 (5%)
Bowel/bladder comp (N=15)	3 (20%)	11 (73%)	1 (7%)

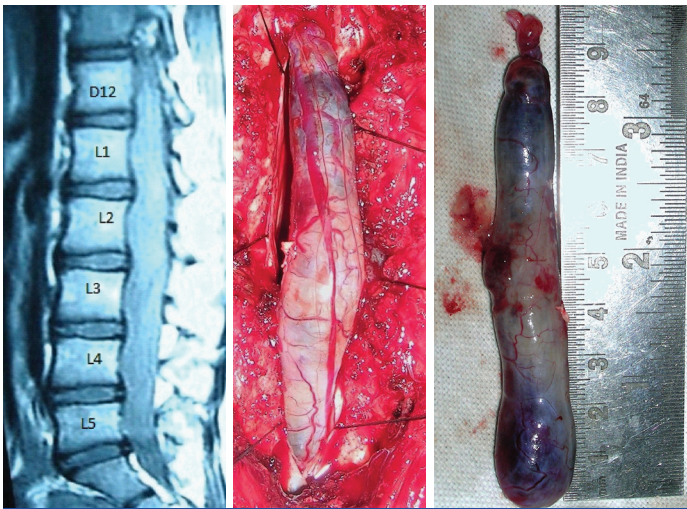
[Table/Fig-3]: The symptom wise progression during follow up in our series population.

This was despite total excision of the tumour. Patients who had fair functional outcome were predominantly those who had residual or recurrent tumours. Majority of these patients had minimal

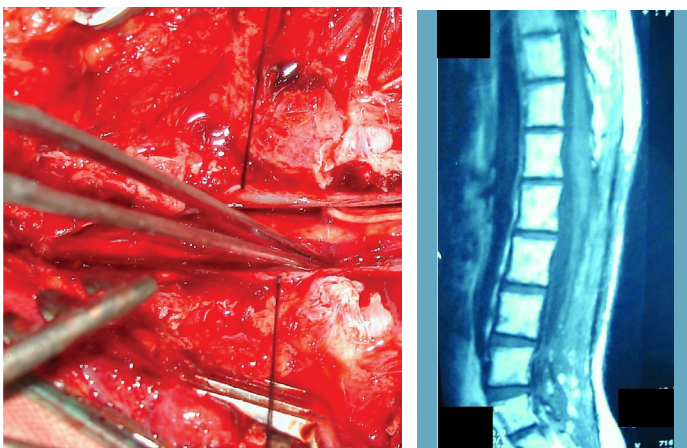
neurological deficits at the time of presentation and excision of the tumour was near total to total.

Illustrative Cases

Case 1: A 27-year-old female presented to us with back pain and difficulty in walking. MRI showed an homogenously enhancing SOL from D12- L5 [Table/Fig-4]. D12- L5 laminectomy with midline durotomy was done. The tumour was visualized [Table/Fig-5] and total excision of tumour was done. The tumour was soft, fleshy and vascular. [Table/Fig-6]. Following tumour excision the rootlets were decompressed [Table/Fig-7]. The postoperative MRI showed



[Table/Fig-4]: Shows post contrast T1W sagittal image of the lumbo-sacral region with the ependymoma at D12-L5 level. The lesion enhances homogenously following contrast administration.
[Table/Fig-5]: Shows tumour seen protruding out on opening the dura. The ependymoma is fleshy and reddish purple in colour.
[Table/Fig-6]: Gross specimen showing the dimensions and character of the tumour.



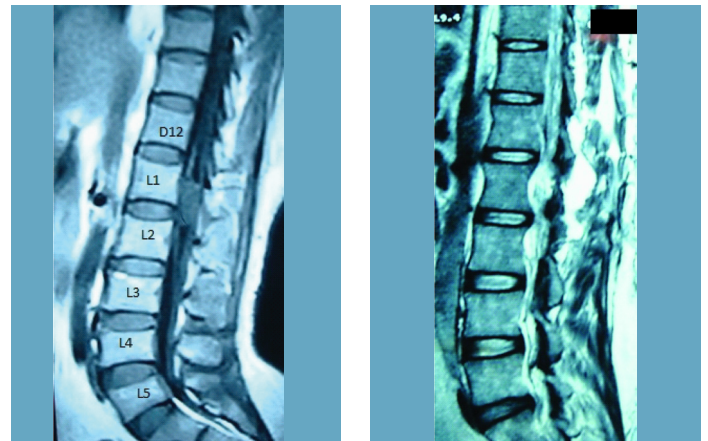
[Table/Fig-7]: Shows nerve rootlets and the conus medullaris on total excision of the ependymoma. **[Table/Fig-8]:** Shows postoperative sagittal T1 image demonstrating complete excision of the tumour with no evidence of any residue.

complete tumour excision [Table/Fig-8]. Patient improved in her symptoms.

Case 2: A 45-year-old male with back pain, difficulty in walking and frequency of micturition had a short segment tumour at L1-L2 level [Table/Fig-9]. Laminectomy with total excision of tumour was performed as seen in Postoperative MRI [Table/Fig-10]. Patient had a good outcome with complete relief in symptoms.

DISCUSSION

Spinal cord tumours have a long and well documented history. Victor Horsley is credited with the first successful removal of a



[Table/Fig-9]: Shows post contrast T1W sagittal image of the lumbo-sacral region with the ependymoma at L1-2 level. The lesion enhances homogenously following contrast administration.
[Table/Fig-10]: Shows postoperative T2W sagittal image with total excision of tumour and CSF filled cavity.

spinal cord tumour in 1887 [5]. Cushing was the first to remove an intramedullary ependymoma in 1905 [5]. Bailey was the first to describe ependymoma in 1924. Elsberg stressed that tumours with well defined planes allow for total removal [17]. Kernohan in 1932 was probably the first to use the term myxopapillary for those ependymomas of the lumbo-sacral region, where mucinous change was conspicuous [7].

We have retrospectively analysed our series of 44 cases of conus cauda ependymoma and have compared our results with 3 other series in world literature: Mathew and Todd, Sonneland et al., and Mork et al., [4,11,18] [Table/Fig-11].

The presentation of symptoms in our series was early when compared with Sonneland and Mork et al., as we had the advantage of having MRI scan at our discretion [4,11]. Hence, the diagnosis of tumour was relatively early.

In our series total excision of the tumour was done in 39 (89%) patients. In only 5 patients near total to subtotal excision was done (11%). This was possible due to routine use of microscope and microsurgical techniques. In comparison total excision was done in 45 (58%) patients by Sonneland et al., and in 32 (42%) patients subtotal to near total excision was performed [11]. Similarly; Mathew et al., and Mork et al., had total excision in 1 (14%) and 13 (54%) patients respectively [4,18]. This can be attributed to pre-microsurgical era when the use of microscope and microsurgical techniques were not very popular.

Myxopapillary variant of ependymoma was the commonest histological findings in Sonneland et al., (100%) and Mork et al., series [4,11]. In our series the incidence of myxopapillary variant was 55% followed by cellular type (39%).

In our series, radiotherapy was not given in patients where total tumour excision was performed. Radiotherapy was given in only

Authors, year	Sample Size (n)	Study duration	Age Range (median), in years	Female Gender n (%)	Symptom duration range (median), months	Presenting symptoms (%)	Surgical resection n (%) / RT (%)	Recurrence rate (%)
Mathew & Todd, 1993 [18]	7	1971- 1989	9 – 52 (37)	1 (14.3)	1-36 (3)	BP (71) SMD (86) BBD (71)	GTR – 1(14)/0 STR – 6(86)/83	Data unavailable
Sonneland et al., 1985 [11]	77	1924- 1983	6 – 82 (36.4)	29 (37.7)	1-360 (18)	BP (96) SMD (53) BBD (3) SD (36)	GTR – 45(58)/82 STR – 32(42)/84	9
Mork et al., 1977 [4]	32	1953- 1974	3 – 80 (32)	12 (37.5)	1 – 120 (12)	BP -Commonest	GTR – 32(54)/85 STR – 11(46)/90	Data unavailable
Present study	44	2001 - 2015	3 – 63 (31)	9 (20.5)	1 – 36 (10)	BP (91) SMD (84) BBD (34) SD (14)	GTR – 39(89)/0 STR – 5(11)/100	5

[Table/Fig-11]: Patient characteristics from relevant literature depicting outcomes in patients with conus cauda ependymoma. BP- Back Pain, SMD- Sensory Motor disturbances, BBD – Bowel bladder disturbances, SD- Sexual disturbances, GTR- Gross total Resection, STR – Subtotal resection

5 patients where the excision was near total to subtotal. Similarly, in series by Mathew et al., radiotherapy was given to patients with subtotal excision [18]. Radiotherapy was given in group with total tumour excision in addition to subtotal group in Sonneland et al., and Mork et al., series [4,11]. This was attributed by them to their philosophy of high incidence of recurrence in patients with total tumour excision who did not receive radiotherapy. Sonneland also stressed en-bloc complete excision of the tumour instead of piecemeal excision and advocated postoperative radiotherapy in cases with total excision done by piecemeal fashion.

Residual/Recurrence rates: There were no significant series except Sonneland et al., available in literature to compare the data for recurrence/ residual tumour. Sonneland found recurrence in 7 patients in their series. In 2 patients of which the excision was total, whilst in 5 patients the excision was subtotal. Radiotherapy was subsequently given in 6 patients with recurrence of tumour [11]. In our series, recurrence was noted in 2 patients in whom the excision was near total and had received radiotherapy.

LIMITATION

This is a retrospective study and single institute experience. These drawbacks may limit generalization of results.

CONCLUSION

Conus cauda ependymomas are relatively benign tumours. The long term prognosis is excellent with respect to recurrence and functional outcome in cases with complete tumour excision. Early diagnosis and surgery will prevent occurrence of permanent neurological deficits. Radiotherapy can be given in cases of subtotal excision but there is limited role of radiotherapy in cases with total tumour excision.

REFERENCES

[1] Bailey BM, Elvidge AR. Ependymomas: A clinical survey. *Jr Neurosurg.* 1970;33:428-38.

- [2] Shaw EG, Evans RG, Scheithauer BW, Ilstrup DM, Earle JD. Radiotherapeutic management of adult intraspinal ependymomas. *Int J Radiat Oncol Biol Phys.* 1986;12:323-27.
- [3] Fokes EC, Earle KM. Ependymomas: clinical and pathological aspects. *Jr Neurosurg.* 1969;30:585-94.
- [4] Mork JS, Loken AC. Ependymoma: A follow up study of 101 cases. *Cancer.* 1977;40:907-15.
- [5] Adams CB, Fearnside MR. Tumours of the cauda equine. *J Neurol Neurosurg Psychiatry.* 1978;41(1):24-31.
- [6] Bailey P. Tumours arising from ependymal cells. *Arch Neurol Psychiatr.* 1924;11:1-27.
- [7] Kernohan JW. Primary tumours of the spinal cord and intradural filum terminale-cytology and cellular pathology of the nervous system. New York: Paul B Hoeber. 1932;3:993-1025.
- [8] Russel DS, Rubinstein LJ. Pathology of tumours of the Nervous system ed 4. Baltimore: Williams and Wilkins; 1997: 203-19.
- [9] Carson BS, Guarneri M. Ependymoma. *Youmans Neurological Surgery*, 5th ed Saunders; 2004: 1043-51.
- [10] Hans JS, Kaufman B, El Yousef SJ. NMR Imaging of the spine. *Am J Radiol.* 1983;141:1137-45.
- [11] Sonneland PR, Scheithauer BW, Onofrio BM. Myxopapillary Ependymoma: A clinicopathologic and immunocytochemical study of 77 cases. *Cancer.* 1985;15:883-92.
- [12] Epstein FJ, Farmer JP, Freed D. Adult intramedullary spinal cord ependymomas: The result of surgery in 38 patients. *Jr Neurosurg.* 1993;79:204-09.
- [13] Cristante L, Herrmann HD. Surgical management of intramedullary spinal cord tumours: Functional outcome and sources of morbidity. *Neurosurgery.* 1994;35:69-76.
- [14] Sjougros S, Malluci CL, Jackowski A. Spinal ependymomas: The value of postoperative radiotherapy for residual disease control. *Br J Neurosurg.* 1996;10(6):559-66.
- [15] Fassett DR, Schmidt MH. Lumbosacral ependymomas: a review of the management of intradural and extradural tumours. *Neurosurg Focus.* 2003;15(5):E13.
- [16] Guidetti B, Mercuri S, Vagnozzi R. Long-term results of the surgical treatment of 129 intramedullary spinal gliomas. *Jr Neurosurg.* 1981;54:323-30.
- [17] Elsberg CA. Some aspects of the diagnosis and surgical treatment of tumours of the spinal cord: With a study of the end results in a series of 119 operations. *Ann Surg.* 1925;81(6):1057-73.
- [18] Mathew P, Todd NV. Intradural conus and cauda equina tumours: A retrospective review of presentation, diagnosis and early outcome. *Jr Neurol Neurosurg Psychiatry.* 1993;56:69-74.

PARTICULARS OF CONTRIBUTORS:

1. Assistant Professor, Department of Neurosurgery, TN Medical College and BYL Nair Hospital, Mumbai, Maharashtra, India.
2. Associate Professor, Department of Neurosurgery, TN Medical College and BYL Nair Hospital, Mumbai, Maharashtra, India.
3. Hon. Professor, Department of Neurosurgery, TN Medical College and BYL Nair Hospital, Mumbai, Maharashtra, India.
4. Senior Resident, Department of Neurosurgery, TN Medical College and BYL Nair Hospital, Mumbai, Maharashtra, India.

NAME, ADDRESS, E-MAIL ID OF THE CORRESPONDING AUTHOR:

Dr. Srikant Balasubramaniam,
Assistant Professor, Department of Neurosurgery, TN Medical College and BYL Nair Hospital,
Mumbai-400008, Maharashtra, India.
E-mail: srikantbala@yahoo.com

FINANCIAL OR OTHER COMPETING INTERESTS: None.

Date of Submission: Jul 14, 2016
Date of Peer Review: Jul 27, 2016
Date of Acceptance: Aug 06, 2016
Date of Publishing: Sep 01, 2016